



PATIENT

Leeloo Mackinnon

SPECIES

Canine

BREED

French Bulldog

SEX

FS

AGE

2yr

WEIGHT

13kg

INTERPRETED BY

R. McKenzie Daniel,
DVM, DABVP
(Canine and Feline)

IMAGING PERFORMED BY

Dr Sarah Barthelemy

HOSPITAL NAME

Fish Creek Pet Hospital

REFERRING VET

Dr Armstrong

INVOICE

24843

DATE

05/13/2026

PRESENTING CLINICAL SIGNS

Chronic Hx of regurgitation. Abdominal pain and regurgitation

ULTRASONOGRAPHIC EXAMINATION OF THE ABDOMEN

Urinary System

The urinary bladder, trigone, cystourethral junction, and visible pelvic urethra exhibited normal thickness and tone. Anechoic urine was present in the lumen with no evidence of urine/lumen sediment, mineral, or calculi. The ureteral papillae were normal. The ureters were not visible which is normal. No evidence of inflammatory or neoplastic changes was noted.

Normal size and margination were present in the kidneys. A normal 1:3 cortex / medulla ratio and normal corticomedullary definition were maintained. The echogenicity of the cortex was similar to or slightly less than normal liver parenchyma while the medulla echogenicity was hypoechoic to the cortex with no evidence of pelvic dilation. The left kidney measured 5.0 cm in length. The right kidney measured 5.3 cm in length.

The area of the aortic trifurcation was free of pathology.

Adrenal Glands

The left adrenal gland was uniform in size and contour with a uniformly hypoechoic parenchyma. The left adrenal gland measured 0.49 cm width at the caudal pole. The right adrenal gland was uniform in size and contour with a uniformly hypoechoic parenchyma. The right adrenal gland measured 0.58 cm width at the caudal pole.

Spleen

The spleen exhibited a finely textured and homogenous parenchyma which was hyperechoic to the liver and renal cortical parenchyma. The capsule was smooth and regular without apparent expansion. The splenic vasculature at the hilus was normal in volume with no evidence of congestion or thrombosis. Acute to chronic inflammatory, neoplastic, or benign parenchyma changes were not noted.

Liver/Gallbladder

The liver was subjectively normal in size, structure, and contour. The liver parenchyma was uniform and hypoechoic to the spleen with a mild coarse echotexture. Normal vascular volume. The hepatic and portal vasculature were normal in appearance without signs of congestion. The gallbladder was non-distended in size with thin walls and primarily anechoic luminal content. The cystic and common bile ducts were normal.

Gastrointestinal

The stomach presented intact wall layering with a normal wall layer ratio. The lumen of the stomach was empty with mild lumen gas and no signs of ileus, obstruction or foreign material. The area of the gastroesophageal junction was free of overt pathology. The ventral gastric body wall measured 0.60 cm in width. The pylorus wall measured 0.48 cm in width.

The small intestine presented intact wall layering with 1:3 muscularis/mucosa ratio. The lumen of the small intestine was empty with no signs of mechanical/metabolic ileus, obstruction or foreign material.



PATIENT

Normal visible colon wall layers were present with apparent formed feces in lumen.

Leeloo Mackinnon

Pancreas

The parenchyma of the left limb, body and right limb of the pancreas presented isoechoic to the adjacent omental fat. A normal curvilinear capsule contour of the pancreas was present. The visible pancreatic duct was normal. No signs of active inflammation or neoplastic disease was evident.

SPECIES

Canine

Free Abdomen

BREED

No omental masses, overt lymphadenopathy or peritoneal effusion was present.

French Bulldog

ULTRASONOGRAPHIC FINDINGS

Primary

SEX

FS

- Sonographically unremarkable empty stomach and overall small intestine
- Normal area of pancreas
- Normal bilateral adrenal glands

AGE

2yr

INTERPRETATION OF THE FINDINGS & FURTHER RECOMMENDATIONS

WEIGHT

13kg

No evidence of significant visceral, specifically upper gastrointestinal, pancreatic, or overt visible esophageal pathology as an obvious contributing factor to the patient's history. Mild gastritis or esophagitis is suspected.

Smaller, more frequent feedings of a canned bland or hydrolyzed diet with empirical therapy for esophagitis/gastritis, such as gastric protectant protocol i.e., Omeprazole 1 mg/kg PO SID as needed with monitoring of clinical response is recommended.

INTERPRETED BY

R. McKenzie Daniel,
DVM, DABVP
(Canine and Feline)

Although considered unlikely, screening cortisol level to rule out Addisons disease may be considered. If continued or non-responsive gastrointestinal signs, upper gastrointestinal endoscopy is recommended.

IMAGING PERFORMED BY

Dr Sarah Barthelemy

HOSPITAL NAME

Fish Creek Pet Hospital

REFERRING VET

Dr Armstrong

INVOICE

24843

DATE

05/13/2026



PATIENT

Leeloo Mackinnon

SPECIES

Canine

BREED

French Bulldog

SEX

FS

AGE

2yr

WEIGHT

13kg

INTERPRETED BY

R. McKenzie Daniel,
DVM, DABVP
(Canine and Feline)

IMAGING PERFORMED BY

Dr Sarah Barthelemy

HOSPITAL NAME

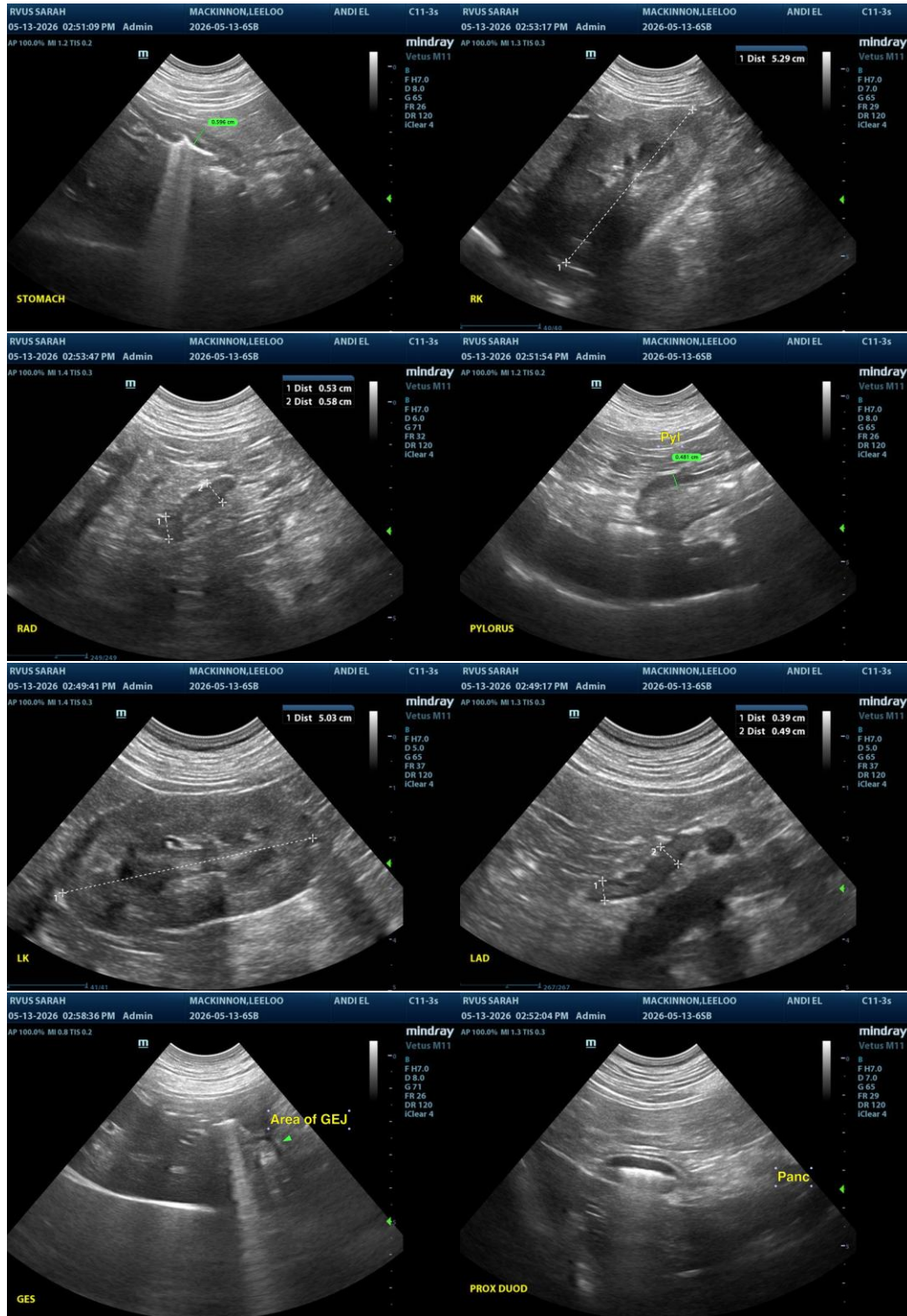
Fish Creek Pet Hospital

REFERRING VET

Dr Armstrong

INVOICE
24843

DATE
05/13/2026



The information and recommendations provided are based on the images presented by the referring veterinarian/sonographer. No evaluation can be communicated regarding pathology that was not



PATIENT

Leeloo Mackinnon

visible in the image/video clips provided.

Thank you for this referral. If the clinical or image interpretation does not parallel your findings or if I can be of any further assistance, please contact me.

SPECIES

Canine

R. McKenzie Daniel, DVM, DABVP (Canine/Feline Practice)
info@sonopath.com

BREED

French Bulldog

SEX

FS

AGE

2yr

WEIGHT

13kg

INTERPRETED BY

R. McKenzie Daniel,
DVM, DABVP
(Canine and Feline)

IMAGING PERFORMED BY

Dr Sarah Barthelemy

HOSPITAL NAME

Fish Creek Pet Hospital

REFERRING VET

Dr Armstrong

INVOICE 24843

DATE
05/13/2026